VCA Veterinary Specialty Center of Seattle

20115 44th Avenue West Lynnwood, WA 98036
425.697.6106 ▪ 425.697.4746 [FAX]

CT Report

Patient: Female ORCA L-112
Date of Study: December 12, 2012
Referring doctor: Whale Museum
Study: Cervical vertebrae and T1
Technical factors: Standard and bone. 1-mm slices

CT Findings: The cervical vertebrae and T1 were scanned as a group attached by a cable tie. There was also an individual scan performed on the fused cranial cervical vertebrae and an individual scan performed on C7.

Cervical vertebrae 1 through 4 are fused (congenital).

There is a small 4-mm in width defect in the right side of the lamina of C7 (the dorsal aspect of the vertebra). The ends are blunted and smooth, and the bony margins of this defect are sclerotic. The spinous process is lacking.

The end plate of C7 is lifting from the cranial and caudal aspect of the vertebral body. There is a small fissure in the endplate affiliated with the elevation.

No fractures of the cervical or 1st thoracic vertebrae are appreciated.

The malalignment is because these are individual bones.

CT Conclusions: Congenital defect or anomaly of the dorsal aspect of vertebra C7 (the lamina of C7) with incomplete fusion of the lamina and incomplete formation of the spinous process. This does not appear to be an acute or traumatic fracture.

Fusion of the cranial cervical vertebrae; this has been noted in other orca specimens as well.

The lifting and fissure of the end plates of C7 is believed to be post mortem and likely a result of skeletal preparation and drying and not evidence of a traumatic injury.

Comments: Skeletal specimens were also reviewed by Karen Kline, DACVIM- Neurology, and Courtney Watkins, DACVS (surgery), and they concur with these findings.

CONTINUED NEXT PAGE

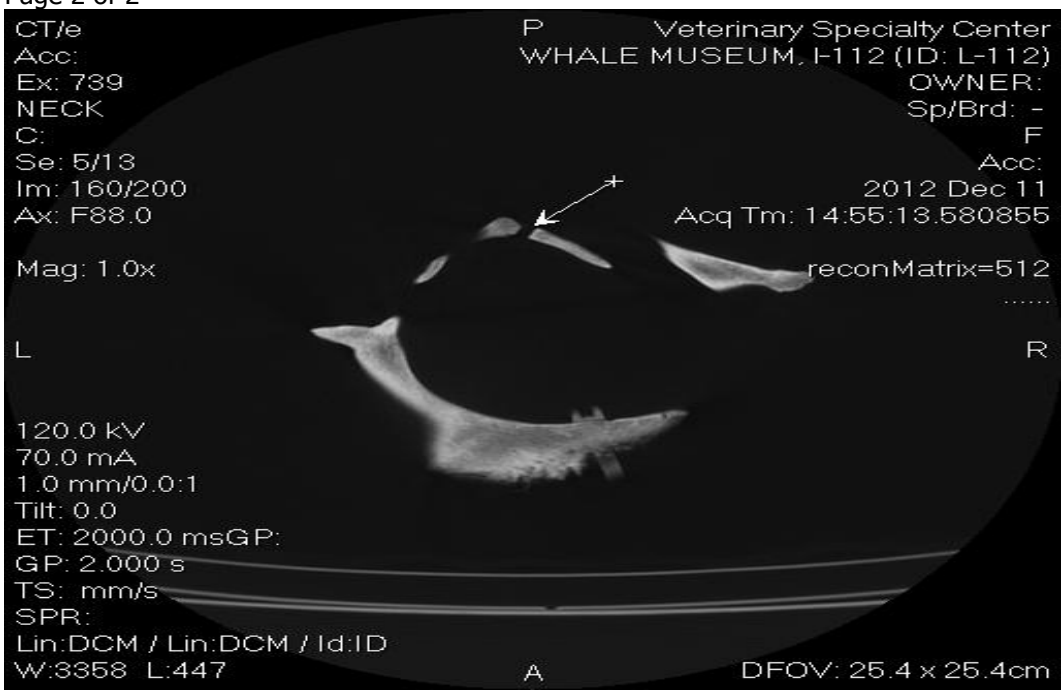

Incomplete fusion of the right side of the lamina of cervical vertebra 7 (arrow)

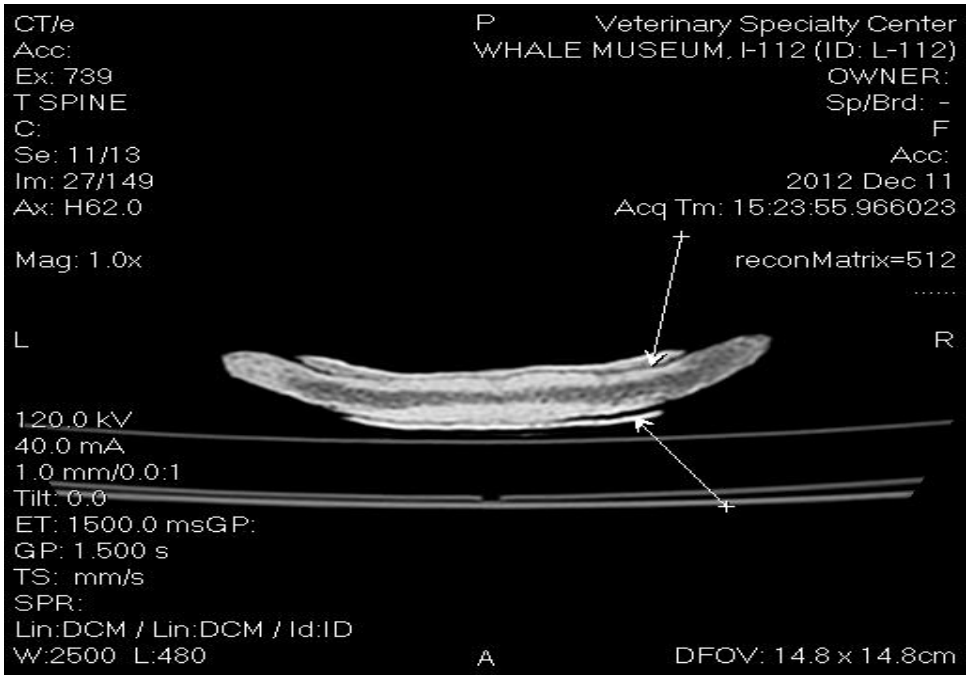

Lifting of the endplates of cervical vertebra 7 (arrows)

Tori McKlveen, DVM, MS, Diplomate ACVR (Radiology)
Karen Kline, DVM, MS, Diplomate ACVIM (Neurology)
Courtney Watkins, DVM, MS, Diplomate ACVS (Surgery)